

7

Open Structure Rhinoplasty

D. W. Kim and D. M. Toriumi

Contents

Introduction	118
Indications	118
Contraindications	118
Alternative Techniques	118
Preoperative Considerations	118
Special Surgical Requirements	119
Preoperative Analysis	119
Surgical Technique	121
Key Technical Points	134
Postoperative Care	134
Complications	135

Introduction

The primary objective of rhinoplasty is to create predictable changes in nasal contour while maximizing nasal function. Reproducible, consistent outcomes in rhinoplasty come with the surgeon's ability to create a stable nasal structure and predict the effects of scar contracture on this structure. In complex cases, endonasal approaches may not provide the exposure needed to execute complex grafting. The external approach allows maximal exposure of the cartilaginous nasal structures, bony vault, and septum. The surgeon is thus able to directly visualize the repositioning, alteration, and augmentation of the nasal structures.

Joseph and Gillies both reported cases utilizing an open approach to rhinoplasty in the early part of the 20th century. Over the ensuing decades, the technique evolved to include a transcolumellar incision which extended onto the vestibular skin allowing for wider exposure. In North America, the approach has steadily gained in popularity since its introduction by Padovan in 1970. Early criticism of the visible columellar scar has been addressed by numerous reports of favorable results with scar camouflage.

One must remember that external rhinoplasty is only a means to access the underlying nasal structures. Once exposure is achieved, there are a multitude of maneuvers that may be executed depending on the patient's individual anatomy. A description of the external approach itself and the maneuvers commonly performed during structural rhinoplasty are presented in the following.

Indications

While there are no absolute indications to external rhinoplasty, there are certain problems which are best corrected through techniques requiring wide exposure. In general these methods involve extensive rearrangement of existing structures or addition of structural grafts. Indications include:

1. Significant tip deformity with an asymmetric, ptotic, overprojected/underprojected, bulbous, or buckled tip structure.
2. Secondary rhinoplasty—previously disrupted structural supports may need to be reconstituted or replaced.
3. Non-Caucasian rhinoplasty—may require significant increases in projection and support of inherently weak alar cartilages.
4. Cleft lip nasal deformity.
5. Crooked nose—may require precise repositioning of upper or lower lateral cartilages (LLC) or extensive septal correction or reconstruction.
6. Major nasal reconstruction.
7. Unclear diagnosis—in cases in which the surgeon is uncertain as to the anatomical cause of the deformity, the external approach allows for accurate diagnosis prior to structural modification.

Contraindications

A relative contraindication to the external approach for rhinoplasty is the presence of severely damaged or thinned skin. Such conditions may occur following multiple previous operations, particularly in thin skinned individuals. The presence of acquired cutaneous telangiectasias, purple or blue discoloration of the nasal skin with cold temperature, and visible irregularities are signs of such a condition. In these cases, an endonasal approach with limited soft-tissue elevation may reduce the risk of further cutaneous compromise.

Alternative Techniques

Although there are no absolute contraindications to the external approach during rhinoplasty, an endonasal approach may be a reasonable alternative in cases in which minimal changes are required.

Nondelivery approaches have the advantage of preserving all major tip support mechanisms of the nose. Access may be gained through a cartilage-splitting or retrograde approach. The main disadvantage of these approaches is the limited exposure of the tip cartilages. While the delivery approach provides greater exposure than nondelivery approaches, it does so at the cost of compromising tip support. Specifically, the intercartilaginous incision disrupts the attachment of the upper lateral cartilages (ULCs) and LLCs. Although the lower lateral crura are widely exposed with this method, the chondrocutaneous flap is delivered in a nonanatomical orientation, creating potential difficulty for the inexperienced surgeon.

Preoperative Considerations

In all rhinoplasty, a clear understanding must be reached between surgeon and patient regarding the perceived nasal deformities, surgical plan, and expected outcomes. The relationship between nasal airway function and appearance must be emphasized.

It is imperative that the patient understand that the postoperative period is a prolonged and dynamic process. Initially, the patient must anticipate a significant amount of swelling which will slowly subside. Over the ensuing months and years, ongoing resolution of edema and contraction of the soft-tissue envelope will create more definition to the nose. The patient must therefore be prepared to wait for several months for a significant improvement from surgery. This is especially true for thick skinned individuals, revision patients requiring extensive manipulations, or patients with only subtle problems. The patient should be aware that the incision on the columella will be visible for several weeks and will fade with time.

Photographic documentation is essential before and after surgery. Full face frontal, oblique, lateral images, and close-up base views are essential. Images should be obtained with dual flash sources angled 45° toward the patient. An additional frontal view taken with a single flash placed in front of and

above the patient allows for shadowing which highlights the dorsal line. A blue screen or wall is ideal for establishing contrast between the patient and background. Standard 35 mm or digital photography are both viable options; at the time of writing, however, slides produced from a high-quality 35 mm camera provide better resolution and color than even the most advanced digital cameras. As technology advances, digital photography may eventually match or surpass traditional methods.

Computer image modification programs are commercially available and are becoming increasingly popular for consultation of cosmetic surgery patients. In rhinoplasty, these programs allow the consultant to alter a downloaded image on a computer screen in order to display the possible postoperative appearance of the nose. Such technology can facilitate a mutual understanding between patient and surgeon regarding surgical goals and expectations. As many patients enter the process with vague or unrealistic wishes or with an esthetic sense that conflicts with that of the surgeon, such programs may help to focus the patient's expectations toward a defined and reasonable goal.

Special Surgical Requirements

The patient should be advised to stop all blood thinning agents such as aspirin, ibuprofen, and vitamin E for at least two weeks prior to surgery. The individual should be in relatively good health and free of active nasal infection at the time of surgery. Any concerning medical condition should be cleared by the patient's primary care physician or appropriate consulting specialist.

It is the preference of the senior author to perform the operation under general anesthetic in order to protect the airway from dependent blood drainage. A single dose of i.v. cephalexin is given prior to the start of the case. If ear cartilage is to be harvested, an antipseudomonal agent such as ciprofloxacin is administered.

A standard rhinoplasty set should be available. The following is a list of essential instruments—the preference of the senior author is indicated in italics:

- #11 and #15 blade scalpels
- Assorted fine skin hooks
- Fine dissecting scissors—*Converse*
- Fine needle holders—*Webster and Castroviejo*
- Fine forceps—*Toothed adson and Bishop-Harmen*
- Tissue forceps—*Brown-Adson*
- Freer elevator
- Retractors—*Converse*
- Suture—*5.0 and 6.0 polydioxanone suture (PDS) for stabilization of cartilaginous grafts; 5.0 clear nylon for permanent suture modification to the shape of native cartilage; 4.0 plain gut on a straight septal needle for closure of septal flaps; 5.0 chromic for closure of vestibular skin incisions; 6.0 PDS for subcutaneous closure of columellar incision; and 7.0 nylon for columellar skin closure.*

Preoperative Analysis

The surgeon must note the thickness and sebaceous quality of the nasal skin–soft-tissue envelope (SSTE). In darker skinned individuals with thick skin, incisions may take longer to heal with increased potential for a visible scar. In addition, the underlying structural framework of the nose must push into the thick soft-tissue envelope in order for form to project through. Moreover, a significant tissue void in such patients will result in exuberant scar formation and poor definition, particularly in the tip and supra-tip areas. Thus the postoperative soft-tissue pollybeak may be prevented by avoiding overreduction of the structural framework of the thick skinned nose and opting instead to achieve balance by augmentation to areas of relative deficiency (Fig. 7.1). In thin skinned patients, there is more tolerance for leaving a small amount of dead space as a greater degree of soft-tissue contracture will allow for “truer” redraping. This advantage in thin skinned noses is counterbalanced by the added risk of contour irregularities becoming visible or palpable. Care must therefore be taken in ensuring that all existing bony and cartilaginous structures, grafts, and implants are precisely positioned and smoothly contoured (1).

It is crucial to obtain a clear idea of the patient's nasal airflow. Many patients present to the rhinoplasty surgeon with functional complaints, while others display variant anatomy which predisposes to postsurgical obstruction. Assessment should be undertaken prior to and after decongestion in order to differentiate between inflammatory and anatomical causes of obstruction. The surgeon must note the external stigmata of an obstructed nose or one that is prone to develop postoperative problems. These characteristics include thin SSTE, a narrow middle vault, short nasal bones, supra-alar pinching, narrow nasal base, a prominent supra-alar crease, narrow nostrils, and thin lateral nasal walls. Intranasal exam may reveal a narrow internal valve angle, dynamic lateral wall collapse, septal deviation, and inferior turbinate hypertrophy. All of these factors must be considered in formulating a surgical plan which will preserve a functional airway.

Cosmetic nasal analysis begins with a global assessment of the most apparent deformities. Often one or two areas are immediately noticeable to the observer. These may include a crooked dorsum, a large dorsal prominence, a bulbous tip, a dependent or foreshortened tip, or a wide base. It is useful to conceptualize a nose in terms of such traits so that priority can be given to these deformities during surgery. In rhinoplasty, each subunit of the nose affects the appearance of the other subunits. Thus, in order to create a natural well-proportioned appearance, the surgeon modifies a given subunit based on the status of adjacent structures. Knowing that one aspect of the nose is particularly problematical allows the surgeon to focus on it and modify the rest of the nose around those corrections. For example, in a patient with a long nose and ptotic tip, the surgeon may wish to establish tip projection and rotation first, and then set the dorsal height appropriate to the new tip position.

Analysis should then continue with a systematic assessment of each view of the nose. While analysis of the patient is done in the office setting, quality preoperative photographs allow for more detailed study at a later time. On the frontal view, symmetry and width should be assessed in each of the

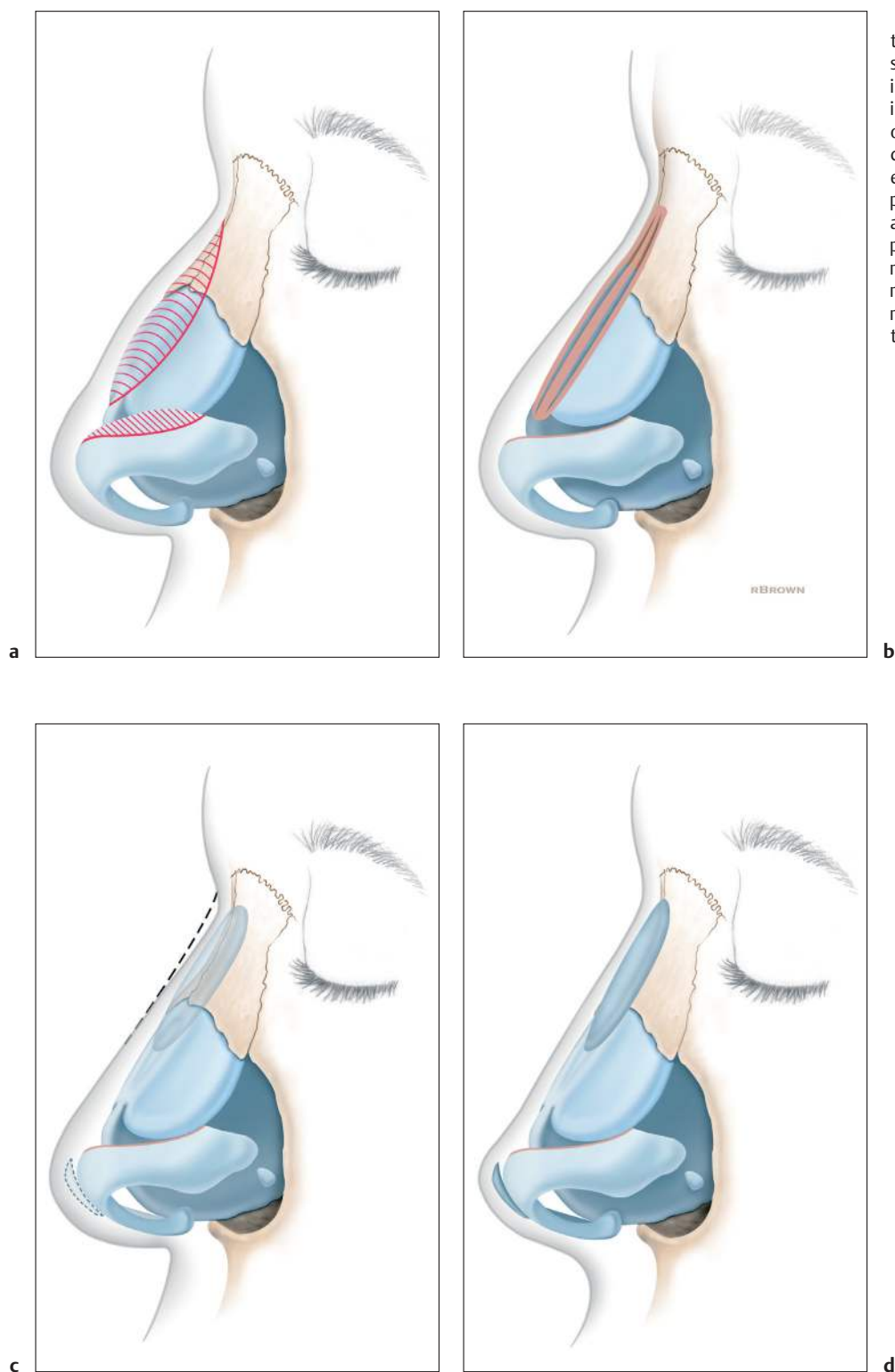


Fig. 7.1 Polybeak deformity due to overreduction of nasal dorsum. (a) A patient with thick skin needs to undergo expansion of structure into the thick skin. Excess reduction can result in a polybeak deformity. (b) Dorsal profile is overreduced, leaving excess SSTE and polybeak deformity. The problem in these patients is the excess, thick nasal tip skin. Reduction of tip projection and loss of dorsal height acts to accentuate the deformity. (c) Treatment of the polybeak deformity may require enlarging the nose by placing a dorsal graft and increasing nasal tip projection. (d) Expansion of the thick nasal skin can improve the tip-supratip relationship and balance the nose.

vertical thirds of the nose. The brow–tip esthetic lines should follow a gentle, unbroken curve following the relative normal variation of nasal width: slightly wider cephalad at the brow/nasal root transition, narrower in the middle vault, and wider again at the tip. If the brow–tip esthetic lines are irregular or asymmetrical, the anatomical cause of the problem should be noted. Bony and cartilaginous vault irregularities are easily discernable with a single light source placed above the patient to enhance shadowing. The general tip shape should be determined from the frontal and base views (e.g., bulbous, deviated,

wide, amorphous, asymmetrical). The base view also provides information about the shape and size of the columella, alar base, nostrils, and lobule. In general, the frontal and base views should reveal a triangular shape of the nose in which the nasal base (interface of nose and face) is wider than the tip and dorsal line. The triangularity of the tip depends on the presence of an unbroken line from the nasal tip–defining points to the lateral alar margin. Poor structural support in this area will manifest as alar pinching or concavity of the alar margins on frontal and base views. In cases of variant anatomy in which

the base is excessively narrow or the tip too wide, the correct relationship must be restored.

On the lateral view, the nasofrontal angle should be approximately 120° . This angle is measured at the nasal starting point and is determined by the height of the radix and the angle of the forehead. A deep nasofrontal angle creates an illusion of a shorter nose, independent of the actual vertical position of the nasal starting point. Conversely, a shallow angle creates an appearance of a longer nose. The dorsum is assessed for smoothness, convexity or concavity, and presence of a supratip break. In the lower third, the overall projection and rotation of the nasal tip must be assessed. Using Goode's method, the nasal tip projection as defined from the alar crease to the tip-defining point, should be just over half the length of the nose. The nasolabial angle in men should be between 90° and 95° and in women between 95° and 105° . This angle can be affected by variations in the size and shape of the upper lip and premaxillary bone. Therefore, the nasolabial angle does not always reflect the degree of tip rotation. The alar-columellar relationship and degree of infratip break should also be noted (2, 3, 5).

Surgical Technique

Incisions—Nuances and Technique

Up to 10 cc of local anesthetic with 1:100 000 epinephrine is placed intranasally in the submucoperichondrial plane on both sides of the septum, nasal floor, and inferior turbinate. This larger volume generally will not cause significant hemodynamic disturbances in a healthy patient. The anesthetic is useful in providing vasoconstriction and hydrodissection. The external nasal SSTE is infiltrated with a smaller volume in order to prevent distortion of the baseline shape. The areas injected include the columella, the intradomal area to the nasal spine, the tip and supratip, and the dorsum and side walls. It is useful to mark the salient anatomy and abnormalities with a pen prior to injection.

The marginal incisions may be scored lightly with a 15 blade while everting the alar rims with a wide skin hook to provide direct visualization. The incision should be designed at the caudal margin of the lateral crura. The cephalic border of the nasal vibrissae is an inconstant landmark that may help in localizing the caudal edge of the lateral crura. Palpation of the cartilage with the back of the scalpel is a more reliable localizing technique. The transcolumellar incision is then made with an 11 blade at the level of the midcolumella in an inverted V orientation. The apex of the V should form an angle approaching 90° (Fig. 7.2). Creating an overly acute angle will increase the chance of skin ischemia and breakdown at the apex. The incision should be connected to the columellar extension of the marginal incisions that follow the caudal margin of the medial crura and lie 2 mm posterior to the lateral border of the columella. Particularly in thin skinned patients and in patients with prominent medial and intermediate crura, these incisions must be placed superficially in order to avoid cutting the underlying cartilage.

Elevation of the soft-tissue envelope is then performed in a supraperichondrial plane. The columellar incision is first opened with Converse scissors. The tips of the scissors should

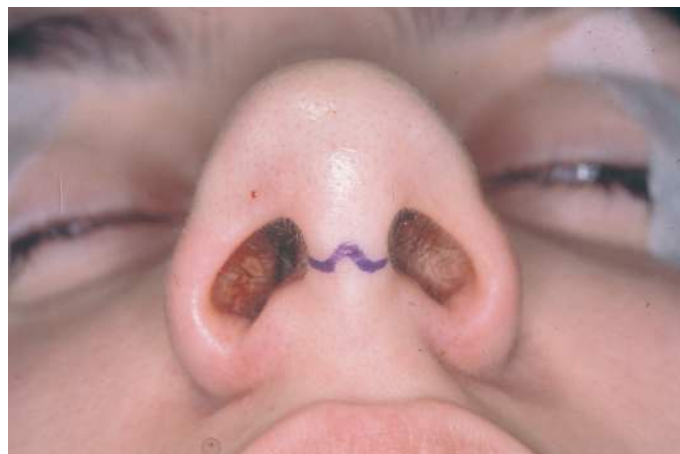


Fig. 7.2 External rhinoplasty approach. Transcolumellar incision made midway between the top of the nostril and base of the nose.

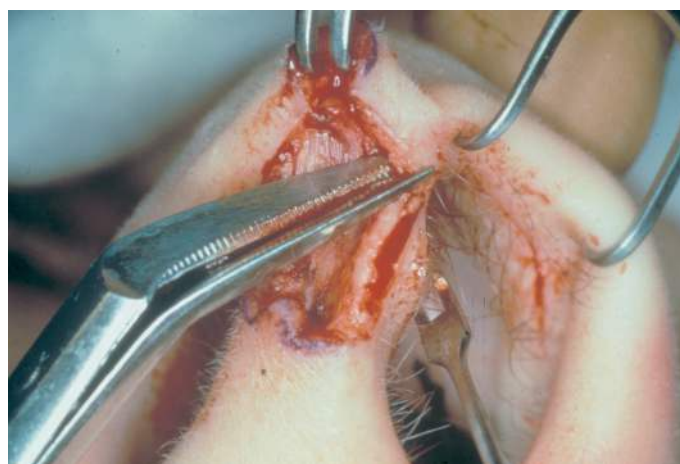


Fig. 7.3 External rhinoplasty approach. Three-point countertraction can aid in delivery of the lower lateral cartilages into the operative field.

be used to establish a tunnel beneath the transverse columellar incision, bridging the two vertical incisions. The scissors should be used as a palpation instrument in this maneuver in order to avoid damaging the underlying medial crura. The scissors may then be gently opened in order to widen the tunnel and to better demarcate the transverse incision. The transverse incision may then be safely completed as the soft-tissue envelope should be elevated from the cartilage at this point. Often there are small columellar arteries at the inferior skin flap that may need to be controlled with a fine tip bipolar cautery.

Elevation of the soft-tissue envelope then proceeds cephalad toward the domes. Three-point retraction greatly aids in the development of the correct plane of dissection. A fine double-prong skin hook retracts the superior flap of the columella cephalically, another fine skin hook is placed at the undersurface of the medial crus in order to retract the intermediate crus and dome inferolaterally, and a third wide double-prong skin hook is placed at the alar rim margin to expose the marginal incision (Fig. 7.3). Dissection is performed with Converse scissors in a plane immediately superficial to the perichondrium. The scissors should be slightly angled downward toward the cartilage and the plane developed with fine cuts using the tips of the scissors rather than through a spreading motion. A cotton-tip applicator may be used as a blunt dissec-

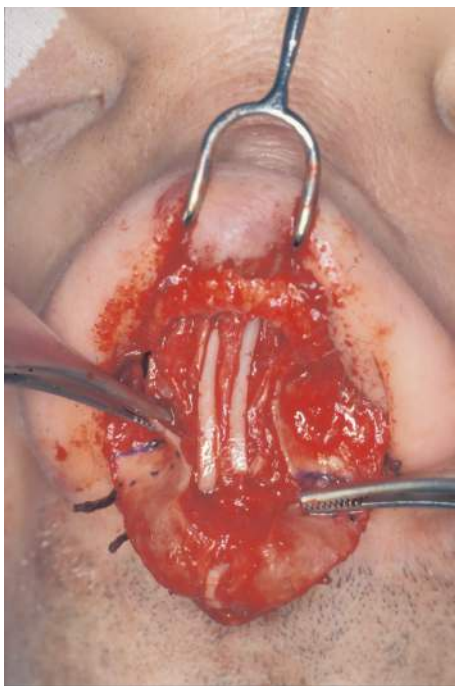


Fig. 7.4 Spreader grafts applied between the upper lateral cartilages and dorsal margin of the septum. Note how the spreader grafts extend from the osseocartilaginous junction to the anterior septal angle.

tor to further develop the plane. As the dissection plane is developed cephalad, the vestibular skin is incised flush with the caudal border of the lateral crura (previously scored). The second fine double-prong skin hook may be advanced laterally on the lateral crus as dissection continues cephalad and laterally. Dissection should be taken to the lateral 25% of the lateral crus in order to gain enough exposure for work in the upper two thirds of the nose. Dissection too far laterally may result in destabilizing the ligamentous lateral support of the LLCs.

Once both lateral crura are exposed, dissection may be continued cephalad over the middle vault. Dissection below the muscle is critical to avoid thinning the overlying skin soft tissue envelope.

Dissection of the soft-tissue envelope over the upper third should be elevated in a subperiosteal plane. Starting at the rhinion, a Joseph elevator is used to incise the periosteum. Dissection proceeds cephalad in this plane. The size of the subperiosteal pocket depends on the planned surgical maneuvers. If significant reduction or rasping of the bony dorsum is needed, a wider area of dissection may be required. If elevation of the radix is planned, a narrow pocket may be preferred for better fixation of the radix graft (1, 3).

Middle Vault

The middle vault has significant functional and cosmetic implications for the nose. Functionally, the internal nasal valve area is partly dependent on the relationship of the ULC and the dorsal septum. Excessive narrowing of the angle between these structures will lead to obstruction at the internal valve. Previous surgery causing destabilization of this area will result in inferomedial collapse of the ULC into the airway. In particular, patients with short nasal bones and long ULCs are at risk of lateral collapse. Cosmetically, the width and symmetry of the

front view of the nose depends on symmetrical reconstruction of the ULC and septum.

Spreader grafts are long rectangular cartilaginous grafts placed between the dorsal cartilaginous septum and ULC. These grafts are useful for correcting functional and cosmetic problems related to a narrow or asymmetrical middle vault. In addition, these grafts should be used in primary rhinoplasty to prevent middle vault collapse in high-risk patients. In particular, when reduction of a cartilaginous dorsal hump leads to excision of the horizontal articulation of the dorsal septum and ULCs, spreader grafts will stabilize the middle vault and help restore appropriate horizontal width.

The dimensions of spreader grafts will vary depending on specific needs and anatomy, but range from 6–12 mm in length, 3–5 mm in height, and 2–4 mm in thickness. More than one graft may be needed depending on available grafting material and the deformities. In general the thicker aspect of the spreader graft is beveled and then positioned cephalad at the rhinion in order to create the normal appearance of slightly increased width in this area. The grafts may be placed from a dorsal approach after the ULCs are freed from the septum. Mucoperichondrial flaps must first be elevated from the junction of the ULC and septum in order to prevent injury to the mucosal lining and subsequent cicatrix. Two 5.0 PDS mattress sutures placed through the ULC, spreaders, and septum should be used for stabilization. The caudal ULC should be pulled caudally during the suture stabilization in order to straighten any redundancy or curvature. The dorsal profile of the spreader grafts, ULC, and septum should be coplanar and smooth. In situ trimming of the grafts may be needed to ensure an even dorsal surface (Fig. 7.4).

An alternative method of placing spreader grafts is through a tight subperichondrial tunnel at the junction of the ULC and dorsal septum. In this method, elevation of the septal flaps must not include the dorsal aspect of the quadrilateral cartilage. A mucoperichondrial incision is made high on the septum just caudal to the junction of the ULC and septum. A narrow dissection instrument, such as a Freer elevator, is then used to create a long, tight pocket just beneath the dorsal junction between the ULC and septum. Snug placement of a spreader graft into this tunnel will cantilever the ULC away from the dorsal septum, effecting additional widening of the internal nasal valve, as compared to placing spreaders through an open dorsal approach. In the latter, the ULC is lateralized, but the absolute angle between the septum and ULC does not change. The precise pocket spreader graft creates lateralization and mild flaring of the ULC, leading to increased width and angulation. This effect is achieved because of the bulk of the spreader graft placed below the intact connection between the dorsal margin of the septum and the ULC. This translates to additional airway improvement. This method should be considered in patients with severe obstruction referable to the internal valve. A drawback to this method is the additional width that is incurred. Careful patient selection is therefore required (3,4).

Other methods to modify middle vault width have been described in the literature and include flaring sutures, suspension sutures, and butterfly grafts (6). In our experience, these methods are less predictable and/or less durable than properly placed spreader grafts.

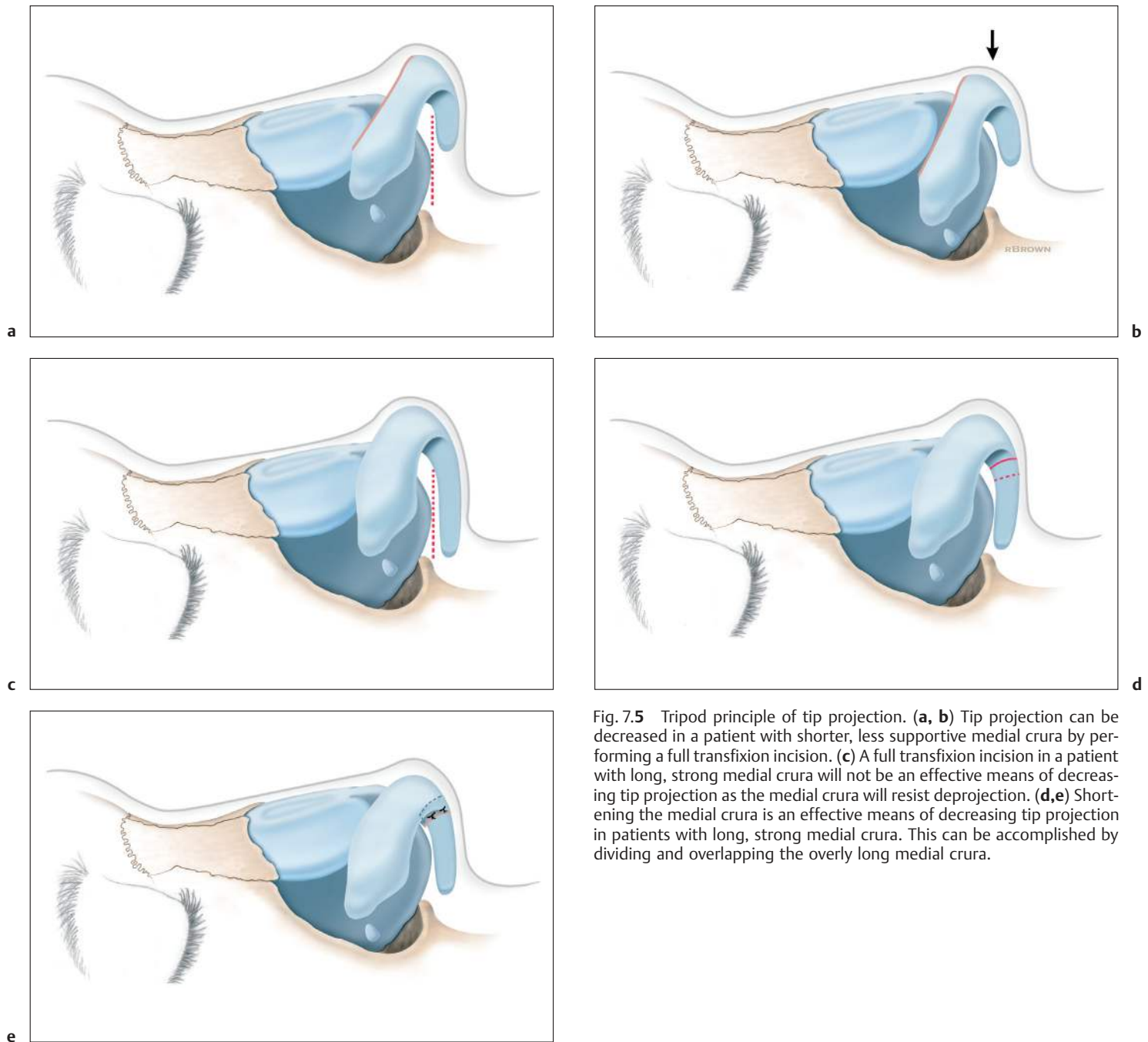


Fig. 7.5 Tripod principle of tip projection. (a, b) Tip projection can be decreased in a patient with shorter, less supportive medial crura by performing a full transfixion incision. (c) A full transfixion incision in a patient with long, strong medial crura will not be an effective means of decreasing tip projection as the medial crura will resist deprojection. (d, e) Shortening the medial crura is an effective means of decreasing tip projection in patients with long, strong medial crura. This can be accomplished by dividing and overlapping the overly long medial crura.

Tip-Base Stabilization

Refinement of the nasal tip is one of the most difficult aspects of rhinoplasty. The external approach allows direct visualization of the underlying variant anatomy which may cause tip deformities. The main variables that are addressed are tip shape and position. Typically, modifications to the inherent shape of the tip are performed through a combination of conservative excision, suture modification, and structural grafting of the LLCs. The specific maneuvers performed vary tremendously, depending on the size, shape, position, and strength of the existing LLCs and caudal septum (1).

Equally important is establishing the appropriate tip position. The projection and rotation of the nasal tip may be con-

ceptualized through Anderson's tripod paradigm. The two lateral crura and the conjoined medial crura create the three limbs of the tripod. Other factors notwithstanding, shortening the medial crura will counterrotate and deproject the tip; lengthening the medial crura will rotate and project; shortening the lateral crura will rotate and deproject; and lengthening the lateral crura will counterrotate and project (Figs. 7.5–7.7). Certain maneuvers will lead to immediate changes to the tripod architecture. These maneuvers may be performed through a combination of *repositioning techniques* such as suture repositioning the medial crura onto the caudal septum in order to decrease projection and rotation; *modification of structural shape* such as dome suturing to increase projection (variable effect on rotation); *structural grafting* such as tip

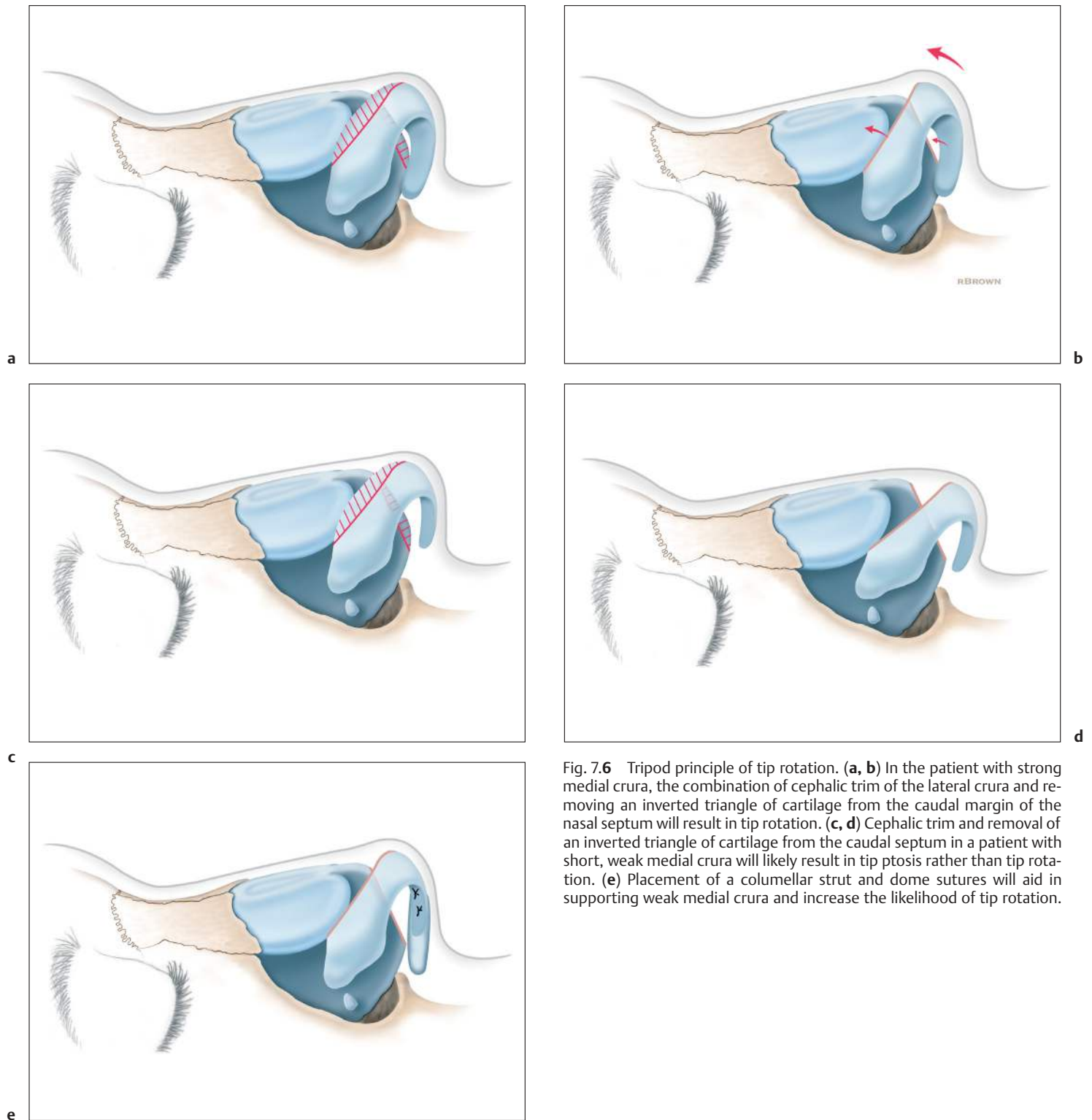


Fig. 7.6 Tripod principle of tip rotation. (a, b) In the patient with strong medial crura, the combination of cephalic trim of the lateral crura and removing an inverted triangle of cartilage from the caudal margin of the nasal septum will result in tip rotation. (c, d) Cephalic trim and removal of an inverted triangle of cartilage from the caudal septum in a patient with short, weak medial crura will likely result in tip ptosis rather than tip rotation. (e) Placement of a columellar strut and dome sutures will aid in supporting weak medial crura and increase the likelihood of tip rotation.

grafting to increase projection; or *overlapping* techniques such as lateral crural overlay in order to deproject and increase rotation (Fig. 7.8). It is preferable to avoid excessive reduction, excision, or weakening of tip structures. Details of refinement to tip shape and position are discussed elsewhere (1, 2, 7).

Often overlooked in rhinoplasty are the dynamic changes that the tip will undergo long after surgery. The combination of the long-term effects of scar contracture, gravity, and mimetic

forces stresses the structural integrity of the nasal tip. Anderson's paradigm is valid only if one understands that the entire tripod is a mobile and compressible structure. The concept of tip support is well-established. The major support mechanisms are the integrity of the LLCs, and the ligamentous attachments between the LLC and the ULC and between the LLC and the septum. Surgical destabilization of these structures often occurs during rhinoplasty. Cartilage excision, morselization,

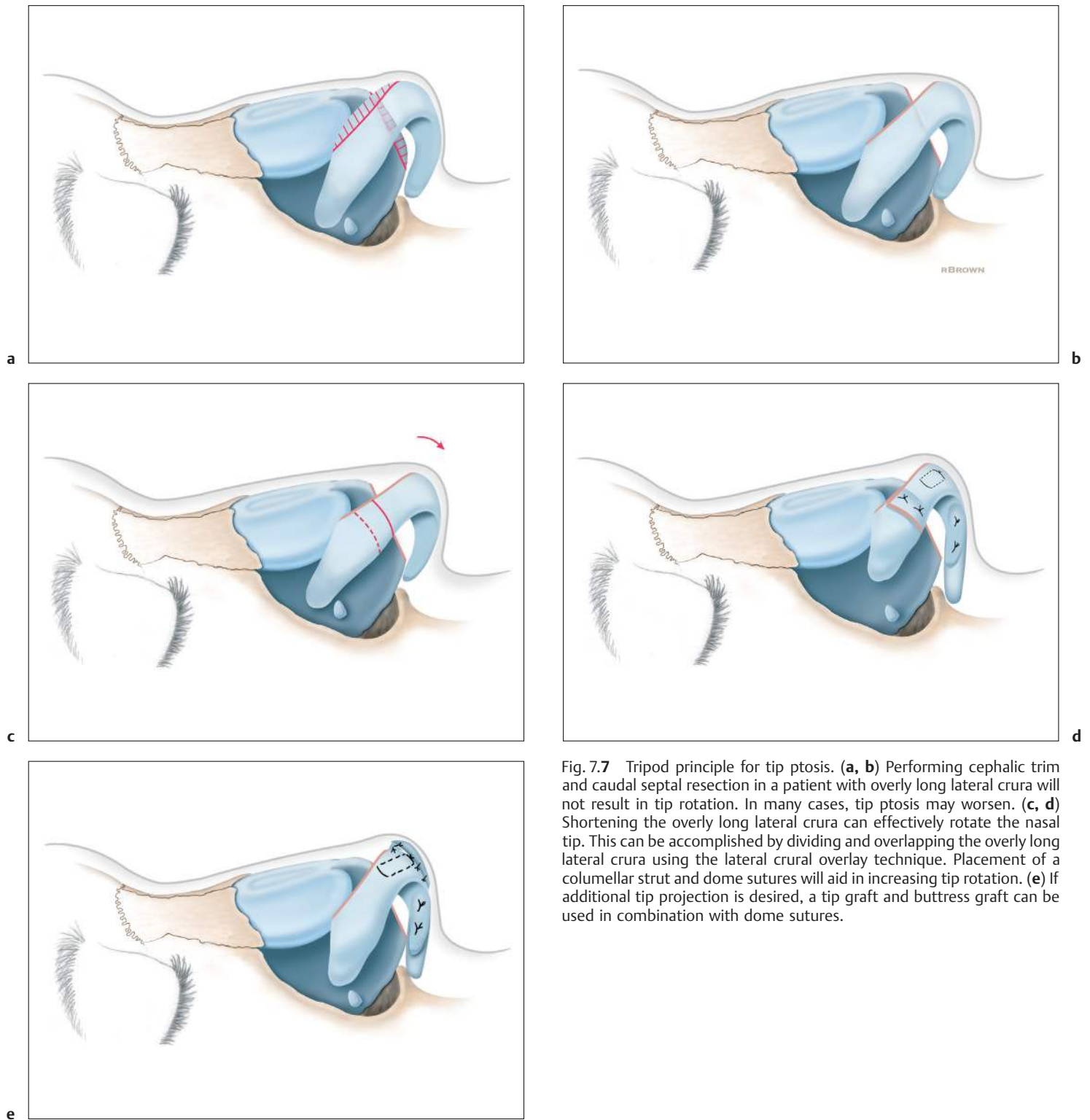


Fig. 7.7 Tripod principle for tip ptosis. (a, b) Performing cephalic trim and caudal septal resection in a patient with overly long lateral crura will not result in tip rotation. In many cases, tip ptosis may worsen. (c, d) Shortening the overly long lateral crura can effectively rotate the nasal tip. This can be accomplished by dividing and overlapping the overly long lateral crura using the lateral crural overlay technique. Placement of a columellar strut and dome sutures will aid in increasing tip rotation. (e) If additional tip projection is desired, a tip graft and buttress graft can be used in combination with dome sutures.

and cross-hatching will weaken the inherent structural support of the tip architecture. Separating the medial crura from the septum and the ULC from the LLC compromise the main ligamentous tip supports. Unless the tip is soundly resupported at the time of surgery, a high risk of postoperative loss of tip projection and tip ptosis is incurred. For these reasons, stabilization of the nasal base is essential in order to achieve durable results in tip modification.

The method chosen to stabilize the nasal base depends on the particular anatomy and surgical goals. Typically, any given method of base stabilization may be adjusted to effect subtle changes in tip projection and rotation as well. The techniques most commonly employed by the senior author include fixation of the medial crura onto the caudal septum, caudal extension graft, suture fixated columellar strut, or extended columellar strut. In each of these techniques, a stable midline

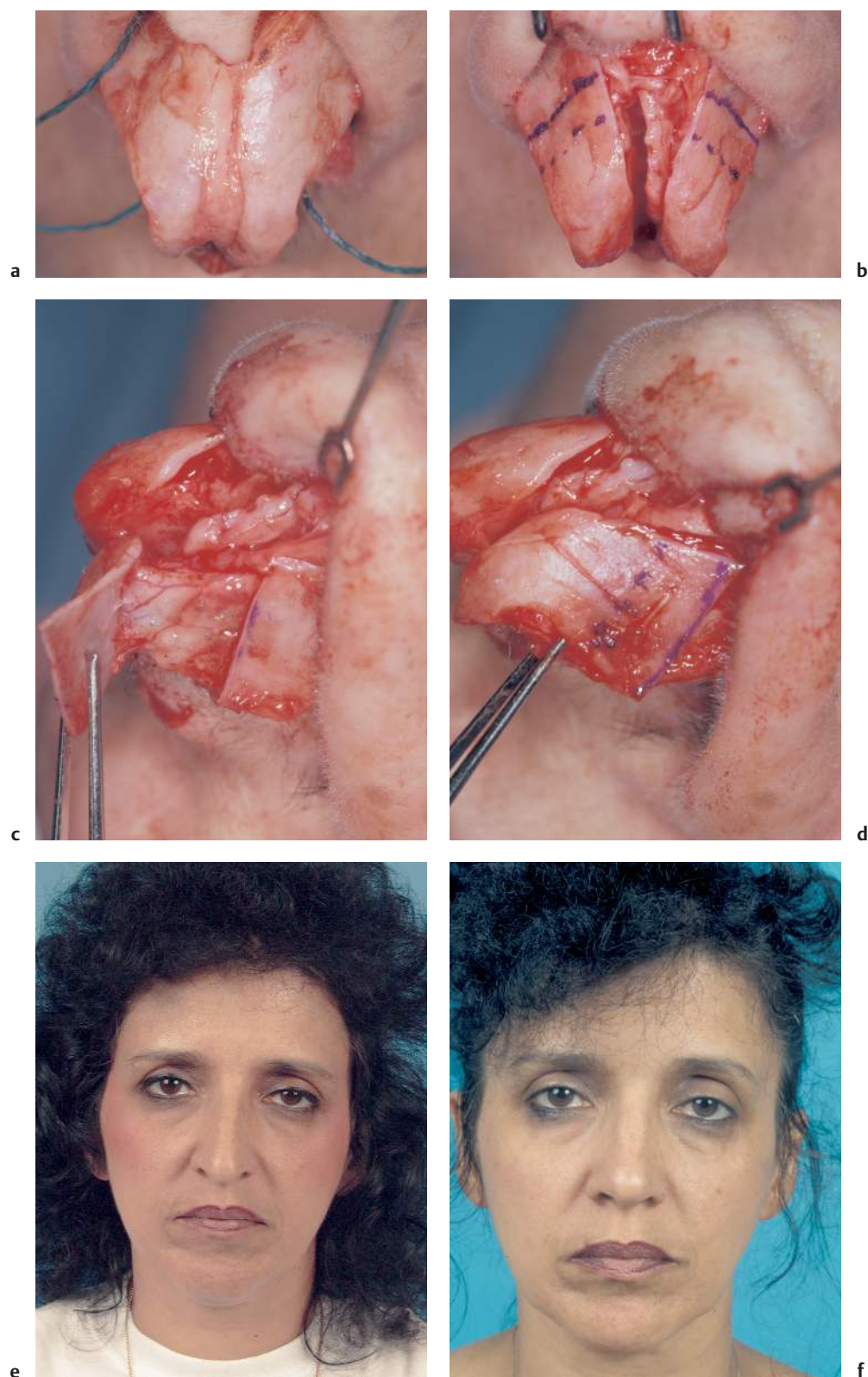
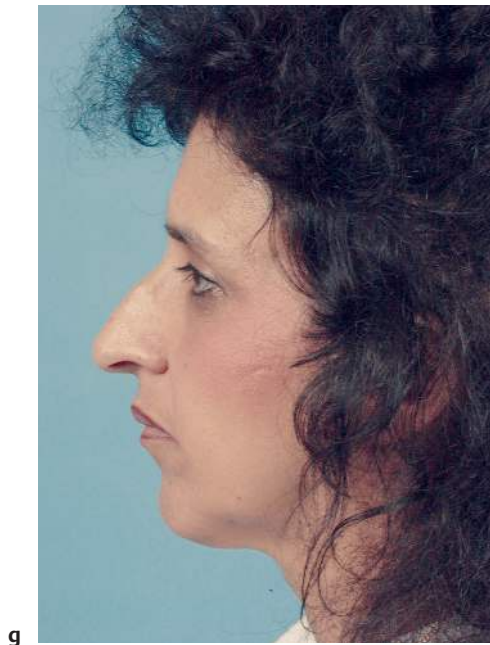
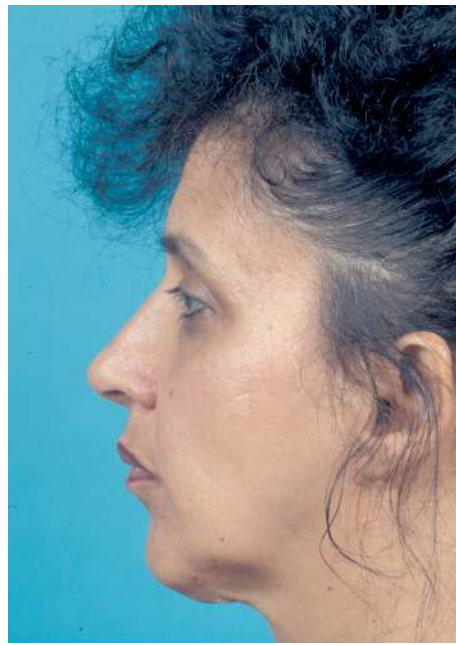
Fig. 7.8 Patient with a dependant nasal tip. Using the lateral crural overlay technique results in shortening of the lateral crura and increased tip rotation. The medial crura were also sutured to the caudal septum to support the nasal base. **(a)** Overly long lateral crura creating dependant nasal tip. **(b)** Lateral crura marked in preparation for lateral crural overlay. **(c)** Lateral crura divided lateral to the domes and cartilage elevated off underlying vestibular skin. **(d)** Lateral crura are overlapped and resutured with 6-0 PDS suture. Preoperative views: **e, g, i, k**. Postoperative views: **f, h, j, l**.

Fig. 7.8



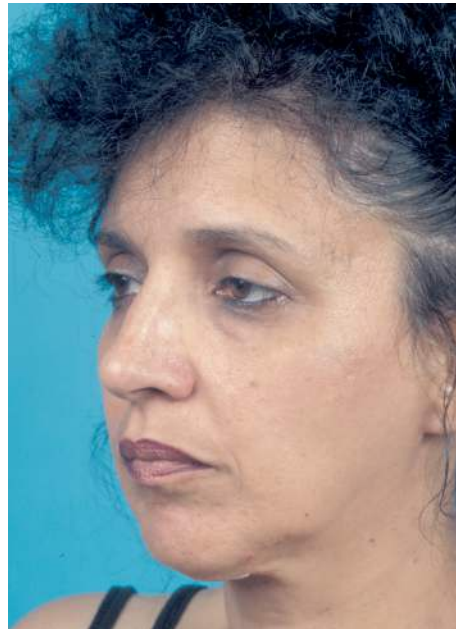g



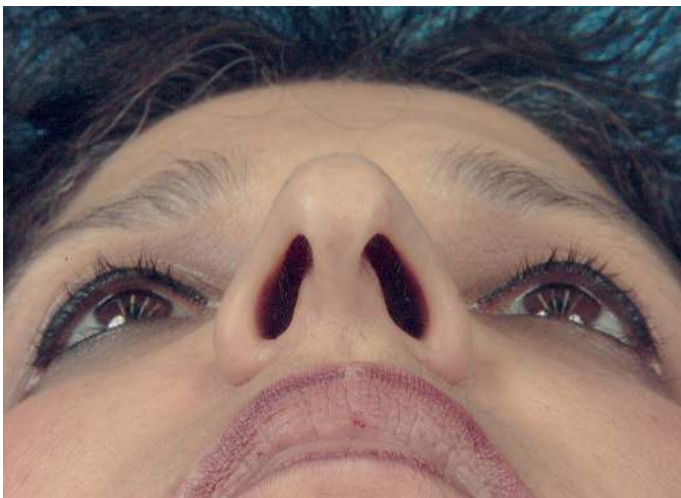h



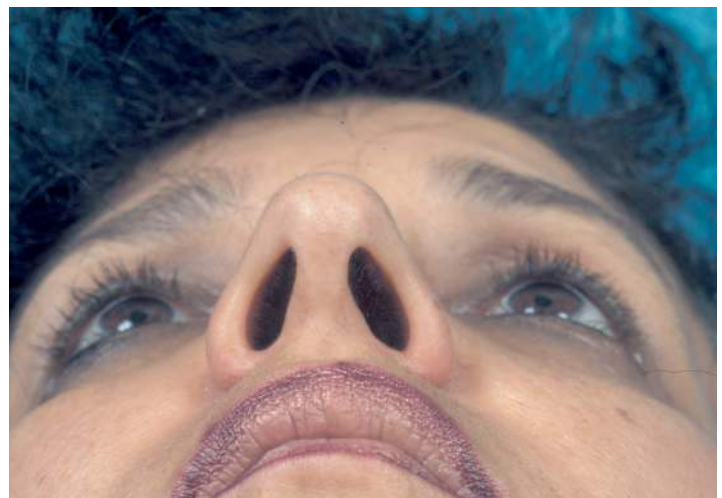
i



j



k



l

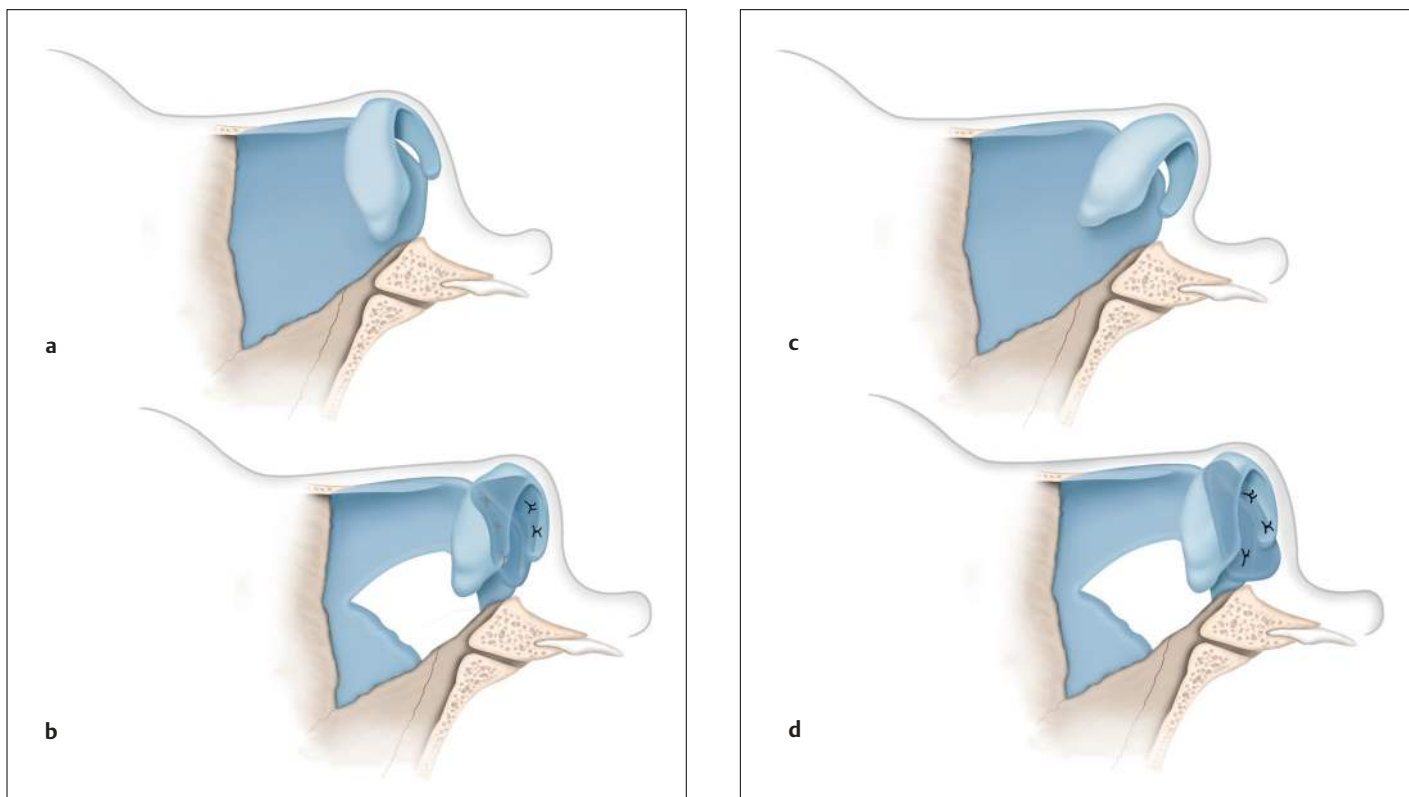


Fig. 7.9 Placement of a caudal extension graft is one method to resupport the nasal base. The shape and orientation of the graft may be altered to effect changes in tip shape and position. (a, b) A graft with a more pro-

jecting anterior margin will allow one to lengthen and counterrotate the nose. (c, d) A graft with a longer posterior margin will allow one to augment the nasolabial angle and create an illusion of increased rotation.

cartilaginous structure is employed to add support to the nasal base and tip. The tripod is effectively stabilized to this structure and may be differentially positioned relative to it in order to create subtle alterations of tip position. Major changes in tip projection and rotation require other techniques.

The medial crura may be suture stabilized onto the caudal septum in patients with a relatively long midline caudal septum. Such patients may present with a hanging columella, tension nose deformity, or overprojected tip and usually require trimming of the caudal septum. If the medial crura are sutured to a normally positioned caudal septum, then retraction of the columella may be created. The medial crura are separated and dissected free of the caudal septum. Bilateral mucoperichondrial flaps are raised on the septum so that mucosal redundancy created by tip repositioning may be distributed cephalically. The medial crura are fixated with horizontal mattress sutures in a tongue-in-groove manner. An initial fixation suture may be placed full thickness through the medial crura, caudal septum, and vestibular skin of the membranous septum with a straight needle and rapidly absorbing suture such as chromic or plain gut. Once the desired positioning is achieved, 5.0 PDS suture may be used to reinforce the fixation between the inner surface of the medial crura and septum. The septal flaps must be redistributed evenly and tightly to the midline with several passes of a 5.0 plain gut suture on a straight needle.

The caudal extension graft relies on the same principle as the previous technique. The difference is that the caudal sep-

tum is effectively lengthened with a cartilage graft so that the medial crura may be readily sutured to it. Patients with a relative caudal septal deficiency may present with columellar retraction and an underprojected, overrotated tip. This technique is often employed in secondary rhinoplasty after previous excessive shortening of the septum. The graft should overlap the existing caudal septum and be suture stabilized with at least two horizontal mattress sutures. The caudal aspect of the graft should be in the midline so that the medial crura may be stabilized in a midline position. Both the caudal septal stabilization technique and the caudal extension graft allow for changes in projection, rotation, nasolabial angle, and columellar show by variably positioning the medial crura onto the septum or caudal extension graft. The latter technique has the potential for a greater degree of tip alteration as the shape and orientation of the effective caudal septal margin may be altered. For instance, if the caudal extension graft is longer anteriorly toward the tip, counterrotation may be achieved (Fig. 7.9a, b). If the graft is longer posteriorly near the nasal spine, the nasolabial angle may be opened with a resultant appearance of increased tip rotation (Fig. 7.9c, d). These techniques rely on the stability of the septum to stabilize the tip. Therefore, the caudal septum itself must be structurally intact and securely attached to the nasal spine and maxillary crest in order to ensure durable stabilization.

The columellar strut is a reliable technique which may be used to stabilize the nasal base. This technique is useful in cases in which major tip alterations are not needed. The strut

should be rectangular and may vary from 5–12 mm in length, 3–6 mm in width, and 1–3 mm thick. The strut is placed in a pocket between the medial crura and sutured to the medial crura in a horizontal mattress fashion. Because the strut does not extend to the nasal spine, it cannot push the tip beyond its existing projection. Thus, while the floating columellar strut will provide some support to the medial crura, such struts may not be adequate for patients with a deficient nasal base.

As a columellar strut extends closer to the nasal spine, a theoretical increase in tip support is gained. The strut, however, must be strong enough to withstand the downward tension of the tip, particularly if it is designed to push the tip beyond its current projection. This is the concept of the extended columellar strut. This technique aims to create a significant increase in projection in patients with a major deficiency of tip support. The non-Caucasian patient and the patient with a congenital nasal deformity often exhibit this scenario. Other anatomical findings indicative of a patient with a deficient nasal base include a ptotic or underprojected nasal tip, and the nasolabial angle may be overly acute. The graft is typically harvested from costal cartilage in order to impart sufficient strength to the nasal base and tip. The strut is suture fixated to the periosteum of the nasal spine. A notch in the undersurface of the strut may be made to articulate with the spine and prevent migration from the midline. Alternatively, the graft may be incorporated with a separate premaxillary graft in a tongue-in-groove manner. This may be necessary in patients with an exceptional degree of premaxillary deficiency. As in the other techniques, the medial crura are sutured to the extended columellar strut to achieve the desired projection.

Once the nasal base is stabilized, we prefer to use dome binding sutures to set the width of the domes. Dome sutures will also provide an increase in tip projection and rotation (Fig. 7.10). Once the width of the domes is set, the distance between the domes can be set with an interdomal suture. This suture goes through both intermediate crura and should not be tied too tight otherwise the columellar lobular angle can be effaced. If a cleft remains between the domes, a small piece of crushed cartilage can be placed between the domes. In cases in which the alar margins are bowed outward or the tip is bulbous, the lateral crura may be convex. Convex or bulbous lateral crura can be improved with dome sutures. Additionally, straightening curved lateral crura may create the appearance of a less bulbous tip. Lateral crural struts are useful grafts in such cases. These flat cartilage grafts are placed between the undersurface of the lateral crura and the vestibular skin. The vestibular skin should be carefully elevated from the lateral crura from cephalad to caudal. The caudal attachment of the lateral crus and skin should remain intact to prevent caudal migration of the graft. The graft should extend from just lateral to the domes to the lateral aspect of the lateral crura. The lateral crural strut graft may be stabilized with a full thickness chromic suture, but should be finally secured to the LLC with a 5.0 clear nylon suture. In patients with thick nasal tip skin we frequently use a sutured-in-place tip graft to provide additional projection and tip contour. Tip grafts frequently measure 10–12 mm in length, 5–7 mm in width, and 2–4 mm in thickness. Tip grafts are sutured to the caudal margin of the medial crura (Fig. 7.11). Tip grafts should not be used in patients with thin skin as these grafts may become visible over time (1).

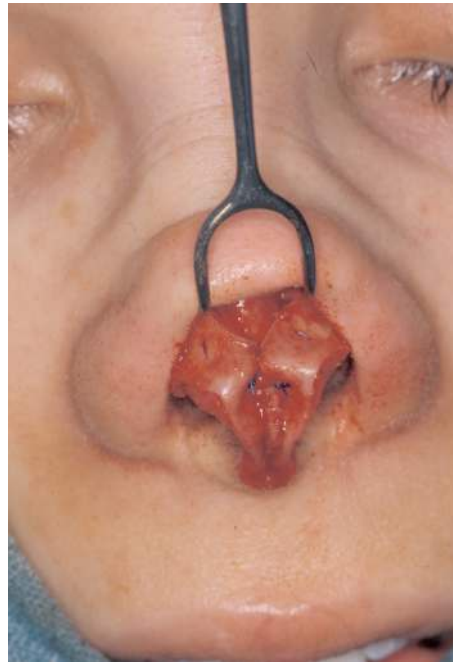


Fig. 7.10 Dome-binding sutures. These sutures are placed through the domes and decrease tip bulbosity and can increase tip projection. An interdomal suture can be used to set interdomal width or a tip graft can be sutured to the medial crura.

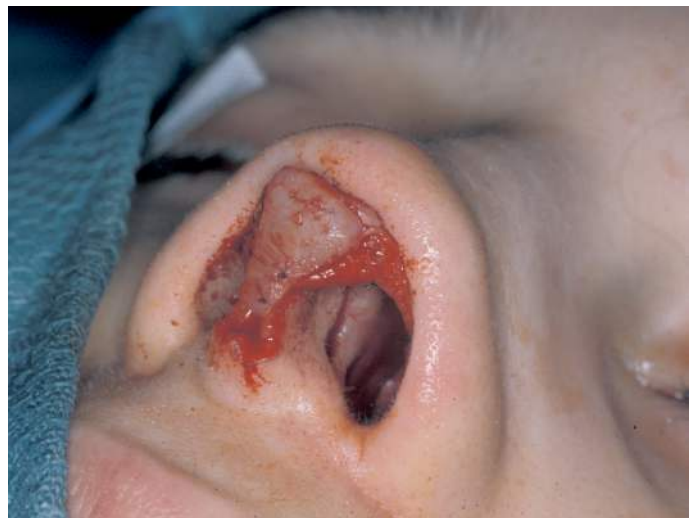

Fig. 7.11 Sutured-in-place tip graft. Note how the tip graft projects a couple of millimeters above the exiting domes. Four to six 6-0 PDS sutures are used to fix the tip graft to the medial and intermediate crura.

Secondary Rhinoplasty

Several special considerations must be made for secondary rhinoplasty. The external approach is an excellent method to gain exposure of the cartilaginous structures as dense scar often impedes dissection. In such cases the direct visualization provided by the external approach may be needed in addition to the tactile feedback upon which endonasal dissection depends. In cases with severe scar formation, even with

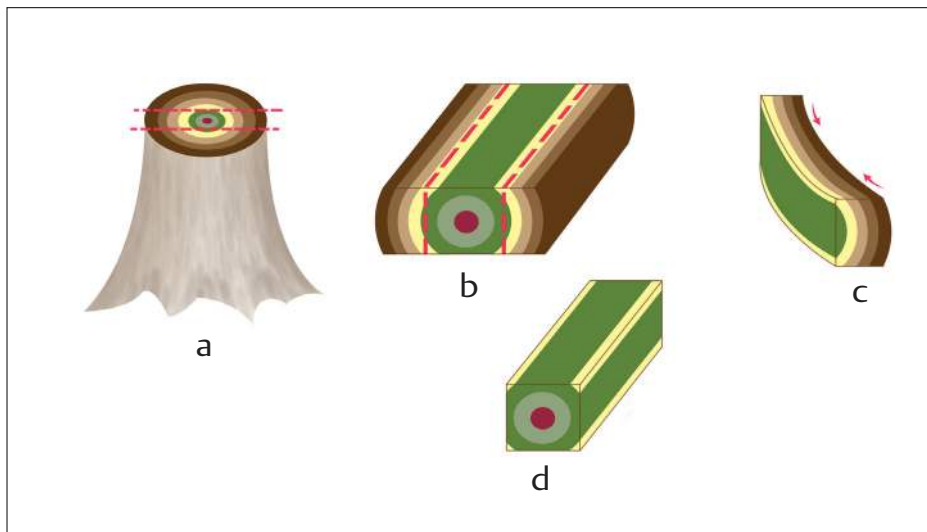


Fig. 7.12 Carving of costal cartilage grafts must be performed in a symmetrical fashion. An effort should be made to obtain the graft from the center of a straight segment of rib. Eccentrically carved grafts will become subject to asymmetrical forces of contracture and have a tendency to warp over time. This concept is illustrated by analogy with a tree trunk with concentric rings. If one carves a graft from the periphery of the trunk, the wood will warp toward the periphery. If one carves a graft from the center of the rings, forces of contracture will be symmetrical and the wood will not warp. (a) A tree trunk has many circumferential rings that create fibrous regions of the tree. (b) If a segment of wood is cut from the tree trunk, opposing fibrous structures can be seen. (c) If the segment is carved asymmetrically, warping can be expected to occur. (d) If the wood is carved symmetrically from the center of the trunk, warping is much less likely.

direct visualization, it may be difficult to differentiate scar from cartilage. As in primary cases, three-point retraction while applying downward pressure with the tips of a pair of Converse scissors will aid in finding and maintaining the correct plane. The surgeon should always protect the integrity of the SSTE.

A common reason patients seek secondary rhinoplasty is for the correction of postoperative nasal obstruction. In such cases, previous surgery has led to overreduction, destabilization, and/or collapse of normal nasal support structures. The most common causes of postrhinoplasty obstruction are lateral wall collapse, middle vault collapse, and persistent or inadequately treated septal deformities. Certain cosmetic stigmata are associated with these functional deficits. These include a narrow middle vault, an inverted V deformity at the cartilaginous-bony junction of the dorsum, supra-alar pinching, and alar pinching. Prevention of these deformities during primary rhinoplasty is a far better option than secondary correction. Avoidance of overresection of the LLCs, stabilization of the base and tip, and reconstitution of the middle vault are key steps in avoiding such complications (1).

One difficulty of secondary rhinoplasty is the lack of septal cartilage available for grafting material. In these cases it is often necessary to harvest cartilage from one or both ears. A vertical skin incision is made approximately 1 cm in front of the postauricular sulcus on the posterior conchal bowl. The skin and perichondrium is then elevated from the posterior concha with Converse scissors. Retraction with a small skin hook and blunt dissection with a cotton-tipped applicator aids in this process. Care should be taken to leave the peripheral vertical component of the concha intact so that no change in shape of the ear occurs. The harvested segment may extend toward the canal meatus, but the eminence corresponding to

the root of the helix should not be excised. The resulting piece is usually kidney shaped and will vary from 2–4 cm in largest dimension. The skin flaps should be judiciously cauterized to prevent thermal injury. Closure with a few subcutaneous 5.0 PDS sutures followed by a running 5.0 fast-absorbing gut should be placed. A bolster in the anterior conchal bowl may be fashioned from a dental roll and sutured through the ear with a 3.0 nylon suture (3).

In cases when ear cartilage is also insufficient or exceptionally strong grafting material is needed, costal cartilage may be harvested. Typically, the cartilage is taken from rib VII, VIII, or IX. A 3–5 cm incision is placed over the medial aspect of the rib. The muscle is separated in the direction of its fibers to access the rib surface. Subperichondrial dissection around the rib is performed with an elevator. It is important to retain a subperichondrial dissection on the deep surface of the rib in order to avoid injury to the pleura. Under direct visualization, the graft is freed from the surrounding perichondrium and the desired segment sharply excised. A malleable retractor may be placed deep to rib to protect the pleura. A needle may be inserted into areas of the rib in which it is unclear whether bone or cartilage is present. Closure should be performed in a layered fashion after hemostasis is achieved (3).

When carving costal cartilage, it is crucial that the surgeon obtain the grafts from the center of a relatively straight segment of rib cartilage. The cartilaginous matrix is circumferentially oriented much like the cross section of a tree trunk. An oblique longitudinal cut will result in asymmetrical forces of contracture and result in warping toward the periphery of the graft. A graft obtained through symmetrical trimming from the periphery toward the center of the rib will result in a graft with equal circumferential forces of contracture and thus a decreased chance of warping (Fig. 7.12).

The presence of damaged or incomplete nasal cartilage poses one of the biggest challenges during secondary rhinoplasty. Components of the structural framework of the nose must often be strengthened or completely reconstructed in order to restore appearance and function. Common problem areas in secondary rhinoplasty include the nasal tip, the lateral nasal wall, the alar margin, and the middle vault.

Postoperative tip weakness may occur if the nasal base is inadequately supported during primary rhinoplasty. In some cases, this manifests as a ptotic, underprojected tip with an acute nasolabial angle. In other cases, concurrent maneuvers such as caudal septal resection or scarring from lateral crural excision may create forces which counteract tip ptosis and result in a tip with normal or excessive rotation, but is none the less poorly supported. The corrective technique depends upon the status of the alar cartilages. Often, the LLCs have been weakened and have lost inherent structural strength. The base must be restabilized through one of the techniques outlined above. In cases of previous caudal septal resection, medial crural stabilization with a caudal extension graft will achieve base stabilization as well as setting tip position. In cases of severe loss of tip support and projection, a costal cartilage extended columellar strut may be indicated.

Tip shape is determined by the size, shape, and orientation of the cartilage of the intermediate and lateral crura. Asymmetries, bossae, bulbosity, and other abnormalities may result from previous surgery. In many cases, the cartilage is so damaged that reorientation of existing structures cannot create adequate tip support. Particularly in thick skinned patients, a robust tip structure must project into the soft-tissue flap to transmit shape through the skin. In such cases, a shield-shaped tip graft may be used to this end. The graft is sutured to the intermediate and medial crura. The dimensions of the shield graft depend on the desired augmentation to the infratip lobule and tip. These structures may be altered without changing the nasal base. The leading edge of the shield graft may project beyond the domes by as much as 8 mm when a significant increase in projection is needed. A buttress or cap graft may be placed cephalad to the leading edge of the graft in order to support the graft and camouflage the transition to the supratip. Lateral crural grafts are placed on the existing lateral crura and sutured to the lateral edge of the shield graft when the tip graft projects more than 3 mm above the existing domes. These also provide additional support and camouflage to the shield graft. Lateral crural grafts also bolster lateral alar support in cases in which the native lateral crura have been weakened or removed.

Lateral nasal wall narrowing and collapse is often the consequence of excessive cephalic trim of the lateral crura. Patients with a long narrow nose and a preexisting prominent supra-alar crease are susceptible to this complication. Examination of such patients may reveal pinching in the supra-alar area with dynamic collapse during inspiration. Correction of this problem requires strengthening the lateral nasal wall and may be performed with alar batten grafts. These grafts are curved cartilaginous supports placed into the area of maximal lateral wall weakness (Fig. 7.13). Through the external approach, the grafts are placed into tight pockets which overlap and extend lateral to the lateral crura. The curvature of the graft should be oriented to lateralize the supra-alar area with the concave surface medial. The lateral aspect of the graft is usually caudal to the lateral crura, depending on the area of

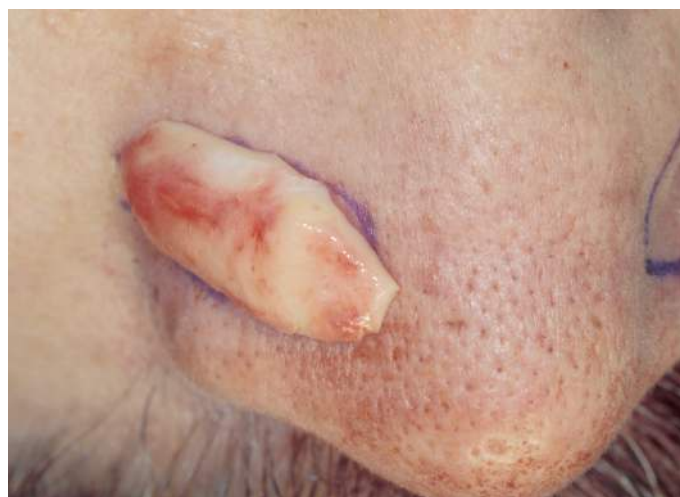

Fig. 7.13 Alar batten graft for lateral wall weakness. Alar batten grafts are placed into precise pockets lateral to the lateral crura along the supra-alar crease.

maximal pinching. In severe cases, the grafts may extend all the way to the piriform aperture in order to add support. In cases in which lateral recurvature of the native lateral crura impinges on the nostril width, the lateral crura may be sutured to the alar batten grafts for lateral stabilization. Internal vestibular stents may be placed in the postoperative period to prevent postoperative medialization of the lateral wall. These stents may be constructed with pliable plastic stents and may be kept in the nasal vestibules at night-time for a period of three to 12 weeks, depending on the severity of the initial problem (1, 8, 9).

Like other complications, secondary deformities of the alar rim may result from overresection or weakening of the alar cartilages. Aggressive cephalic trim may cause cephalic retraction of the alar rim margin and excessive columellar show. Weakening at the alar margin will lead to notching and collapse, most evident by a loss of the favorable triangular base view. Alar rim grafts may be used to correct this type of deficiency. These are narrow cartilaginous grafts which are placed into precise pockets along the alar rim just caudal to the marginal incision (Fig. 7.14). They measure 2–3 mm in thickness and width and 5–8 mm in length. Softer material, such as cartilage harvested from the ear or from cephalic trim of the LLC, is preferable. The medial aspect of these grafts may be gently bruised to aid in camouflage. They may be stabilized to the surrounding soft tissue or to the lateral aspect of a shield graft with 6.0 PDS suture. These grafts will improve upon the concave or “knock-kneed” appearance of the rim on base view and create a more triangular appearance to the basal view (Fig. 7.15). Severe cases of alar retraction may require the use of composite grafts of ear cartilage and skin placed into the marginal incisions to reposition the alar margins in a more caudal position (Fig. 7.16).

Inferomedial collapse of the ULC with associated internal valve collapse, a pinched mid-dorsum, and an inverted V deformity are consequences of destabilization of the horizontal segment of the middle vault. As in primary rhinoplasty, the application of spreader grafts is a valuable tool in restoring middle vault support and symmetry. The same principles apply as in primary rhinoplasty. However, in revision cases, a greater

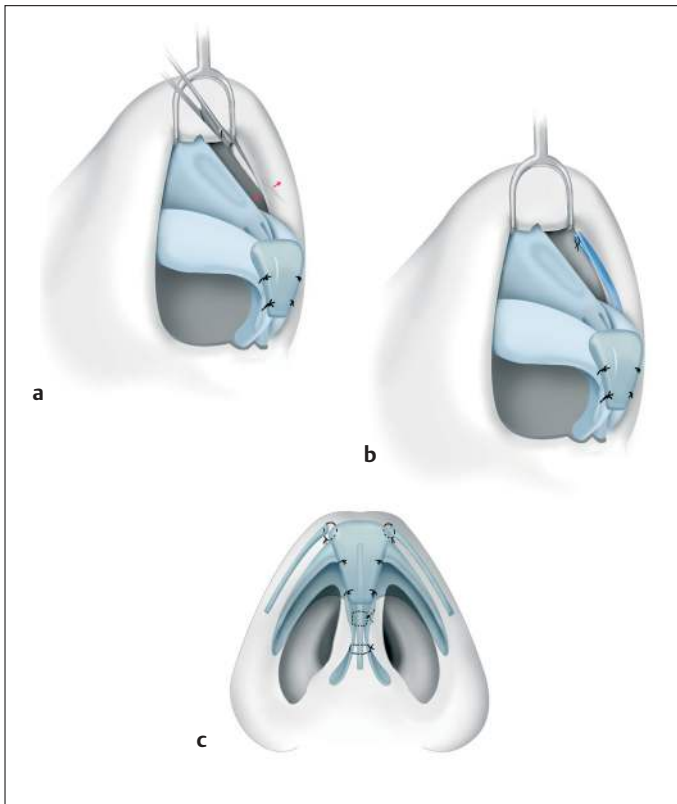


Fig. 7.14 Alar rim grafts are placed into pockets along the alar rims. (a, b) These soft, thin grafts are placed into pockets along the caudal aspect of the marginal incision and extend toward the tip in order to support the alar margin. They may serve to correct mild alar pinching, alar retraction, and can help re-establish a smooth transition from the nasal tip to the base. (c) These grafts may be sutured to the lateral aspect of a tip graft in order to aid in the camouflage and transition of tip structures. Creating a continuous line of support from the tip graft to alar rim significantly decreases the chances of postoperative visibility of the tip graft.

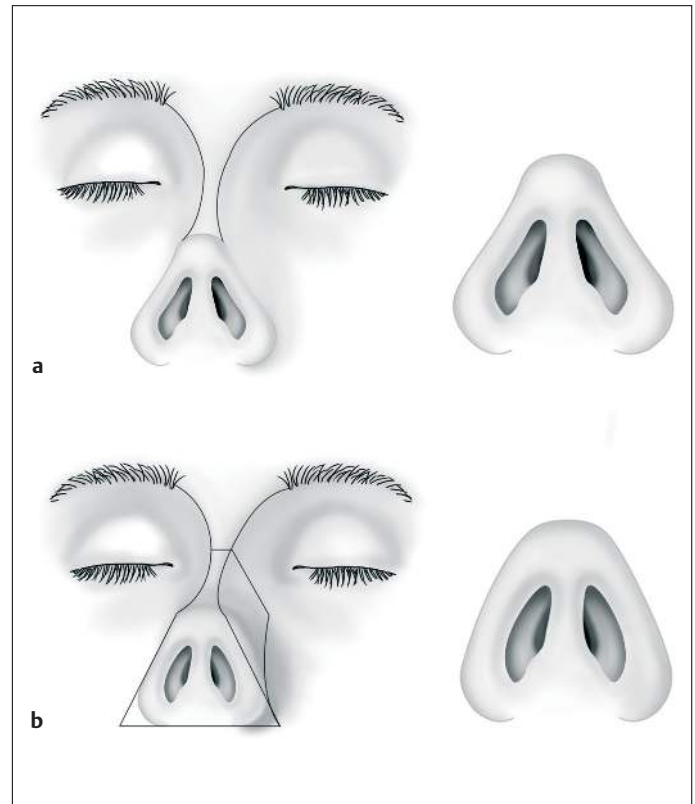
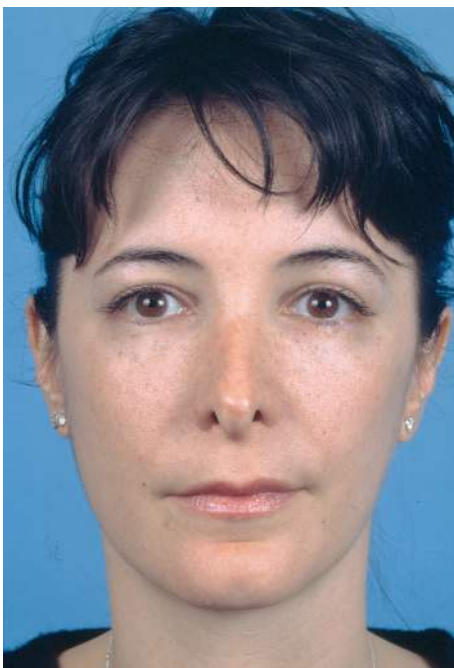
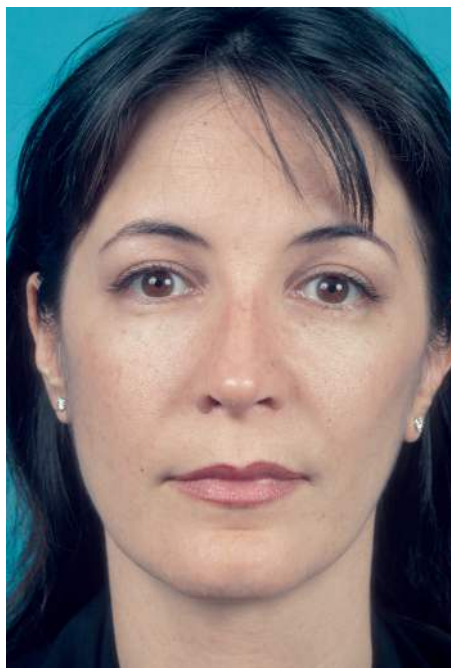Fig. 7.15 When the transition between the tip and nasal base along the alar margin is pinched, irregular, or retracted, there is loss of normal triangularity even if there is appropriate tip width and base width. Placement of alar rim grafts can restore this unbroken transition, re-establishing a natural triangular appearance on basal view and contributing to a normal hour-glass shape on frontal view. (a) Pinched appearance to nasal tip. (b) Normal tip shape with smooth transition from tip to nasal base.



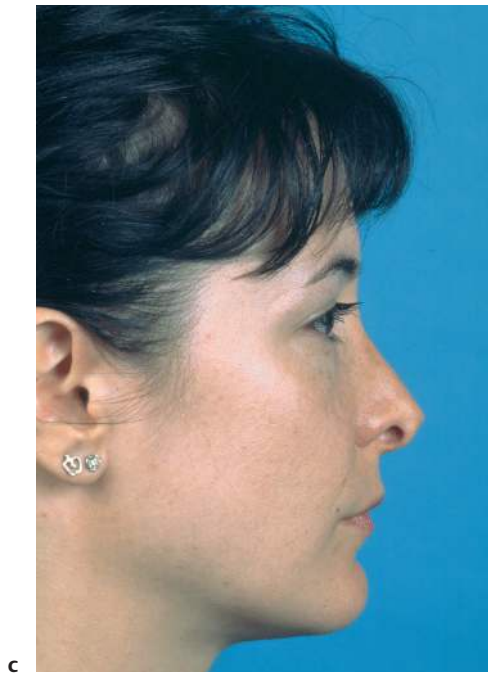a



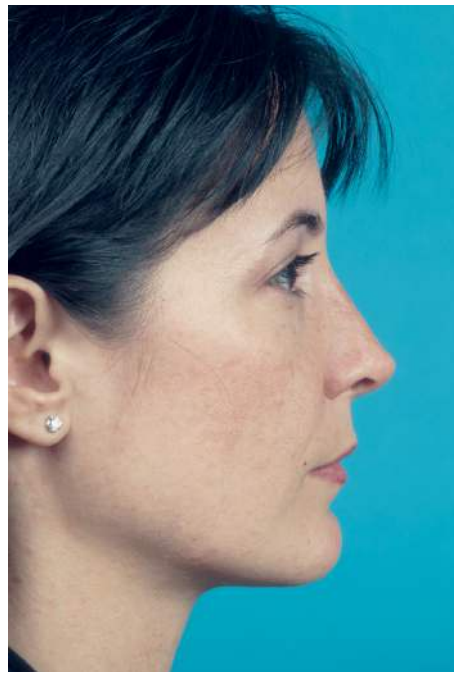b

Fig. 7.16 Secondary rhinoplasty. Patient with pinched middle vault and nasal tip and severe alar retraction. Tip graft was used in combination with lateral crural grafts to reconstruct the nasal tip. Alar batten grafts were used to stabilize the lateral walls of the nose and correct the airway obstruction. Composite grafts were used to correct the alar retraction. Preoperative views: a, c, e, g. Postoperative views: b, d, f, h.

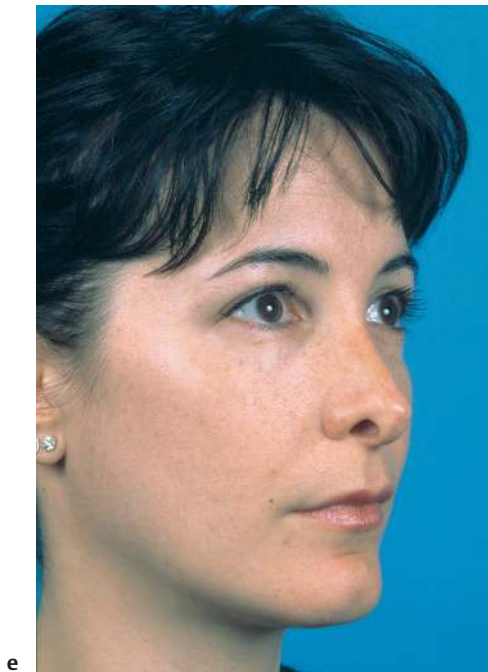Fig. 7.16



c



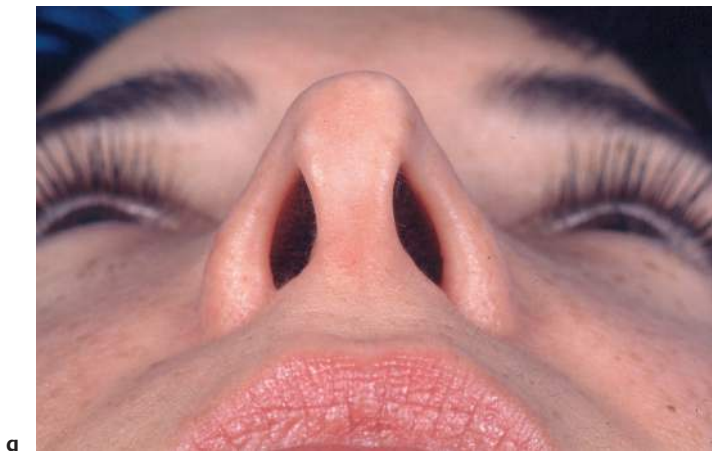d



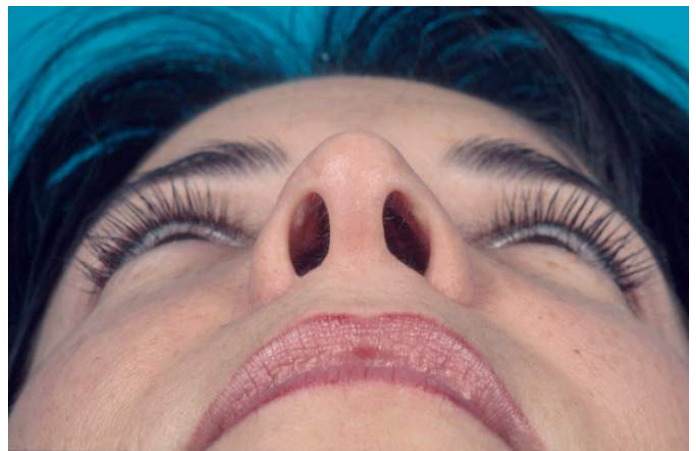e



f



g



h

degree of collapse or asymmetry may be present. The surgeon must therefore be prepared to insert wider or more numerous spreader grafts than in standard primary rhinoplasty.

The osseous vault may demonstrate an assortment of problems related to previous rhinoplasty. Most common are slight asymmetries or irregularities due to unequal osteotomies or inadequate repositioning. A bony open roof may result if previous dorsal hump reduction was performed without lateral osteotomies and medialization of the nasal bones. Treatment of the above problems requires mobilizing the bones through osteotomies, repositioning them into the proper position, and smoothing the dorsal contour as needed. If the dorsum has been excessively lowered, a dorsal onlay graft or a radix grafts may be required. A difficult problem is the case of excessively narrowed nasal bones. Treatment in this case requires osteotomies followed by outfracture of the nasal bones. As the bones will have a tendency to medialize back into their previous position, internal nasal stents may be placed high in the nasal airway to maintain the bones in the proper lateral position (10).

Closure

A single 6.0 PDS subcutaneous suture may be placed in the midline of the columellar incision in order to alleviate tension at the skin closure. A slight degree of eversion should be achieved with placement of this suture. The columellar skin should be closed with several interrupted 7.0 nylon sutures in a vertical mattress fashion. The two sutures just off midline should be angled from medial on the lower flap to lateral on the upper flap in order to better align the skin edges. The edges should be evenly opposed and everted after closure. This will allow for optimal healing over time. The vestibular skin incisions may be closed with interrupted 6.0 chromic sutures. Care should be taken not to distort the alar margin position with the closure of the marginal incision. Bacitracin-soaked Telfa packs are placed in the inferior nasal airway bilaterally to decrease bleeding and the nasal dorsum is supported with tape and an Aquaplast thermoplastic cast. If inferior turbinate work has been done concurrently, small plastic splints are sutured to the septum to prevent synechiae between the septal incision and turbinates.

Key Technical Points

1. A limited volume of local anesthetic should be used in order to prevent distortion of the anatomy.
2. A transcolumnellar incision in an inverted V orientation at the level of the midcolumnella is connected to bilateral marginal incisions.
3. Use of three-point retraction and sharp dissection will allow development of a plane immediately superficial to the perichondrium at the domes, lateral crura, and middle vault.
4. Septal cartilage is approached in a subperichondrial plane through an intranasal hemitransfixion, or Killian incision, or through an external approach with dissection between the medial crura.
5. The upper vault is exposed in a subperiosteal plane with a narrow pocket preserved for possible graft placement.
6. The horizontal junction of the ULC and dorsal septum must be stable and symmetrical. Placement of spreader grafts may aid in restoring support to this area and setting middle vault width.
7. The nasal tip shape and position depend on surgical manipulations to the LLCs. Durable effects depend on stabilization of the nasal base in order to support the tip against forces of scar contracture, gravity, and facial musculature. The main techniques for base stabilization include securing the medial crura onto the caudal septum, caudal extension graft, sutured-in-place columellar strut, and extended columellar strut.
8. Secondary rhinoplasty often aims to correct the functional and cosmetic sequelae of the weakened or deficient structural framework of the nose. Corrective surgery must restore the support structures of the nasal tip, lateral nasal wall, alar margin, and middle vault. The dependable techniques for these problems include shield grafts, alar batten grafts, alar rim grafts, lateral crural struts, and spreader grafts.
9. The columellar incision should be closed with fine sutures and maximal eversion.

Postoperative Care

In most cases, the patient is discharged home a few hours after surgery. Elderly patients or patients with medical conditions which may increase the risks of early complications may be admitted for overnight observation. Antibiotics are given for at least 10 days postoperatively. A first-generation cephalosporin is used for simple primary cases in order to cover skin and intranasal flora. In complex secondary cases, particularly if ear cartilage is harvested, a quinolone such as ciprofloxacin or levofloxacin is used in order to add antipseudomonal coverage. Vicodin is given for pain control, but the patient is encouraged to change to acetaminophen once discomfort begins to subside. The patient is also instructed to clean the nasal lining with hydrogen peroxide on a cotton-tipped applicator and apply Bacitracin ointment over the incisions. The patient is instructed to avoid salt in his/her diet, exertion, and overheating, all of which may induce increased edema.

The patient should return on the first postoperative day for a general check. If significant bleeding has not occurred since surgery, the nasal packing may be removed. If turbinate surgery was performed, the packing may remain for an additional day. The sutures, tape, cast, and ear bolsters are removed between the fifth and seventh postoperative day. The patient should be reminded at this time that significant swelling is expected at this early stage. The internal septal splints are removed two to three weeks after surgery. These should remain longer in cases in which the integrity of the septal flaps is tenuous.

After this point, frequency of follow-up depends on the complexity of the surgery and the individual postoperative course. On average, patients are seen three times within the first month, five to ten more times over the next 12 months, and at least yearly after that. These repeat visits are critical so that the nose may be closely monitored as edema resolves and the SSTE contracts. Over time, slight asymmetries may become apparent at the tip, supratip, or dorsum. If the fullness is com-

pressible, it may be caused by unequal resolution of edema. An area in which more dissection or manipulation was performed may be swollen to a greater degree and duration. If the area of fullness is firmer, it may correspond to a cartilage graft which may have shifted. In either case, the patient may use repeated digital exercises over the area in an attempt to reduce the prominence. The pad of the forefinger or thumb is firmly placed over the palpable fullness several times a day for 5–10 minutes. This will lead to faster resolution of edema in the area and/or gradual shifting of a cartilage graft into a more appropriate position.

Local steroid injection is another technique to improve areas of soft-tissue fullness that are slow to resolve. This technique may help alleviate slight asymmetries that are not fully corrected by digital exercises. Injections will also expedite the resolution of tip and supratip fullness—a process that is particularly extended in the thick skinned patient. Steroid injections may expedite this process. Care should be taken not to inject deep into the dermis more than once every 3 months.

Some irregularities or asymmetries due to cartilage grafts may be refractory to digital exercises. In these cases, a corrective office procedure may be performed under local anesthetic. A 16-gauge needle is placed transcutaneously to access the cartilage graft in question and used to shave the graft into the desired shape. The excised portions of cartilage are selectively crushed and distributed under the skin. A conservative approach should be taken for this procedure in order not to risk overreducing the graft. Additional procedures may be performed so that the desired result may be obtained in a step-wise fashion. If significant imperfections persist despite these efforts, a revision procedure may be required. Usually such a procedure, if needed, is fairly minor and may simply require adjusting the position or shape of a graft. Often, these procedures may be performed under local anesthetic.

Frequent follow-up is crucial in order to detect these abnormalities as early as possible and to correct them through the methods described. Long-term visits are important as the nose continues to change for many years after surgery. Photographs should be taken throughout the postoperative course in order to follow these changes. Only through repeated follow-ups, study of photographs, correlation to operative worksheets, and ongoing analysis will the rhinoplasty surgeon learn from previous mistakes and gain better surgical results.

Complications

Bleeding is the earliest common postoperative complication following rhinoplasty. The placement of packing will help to prevent bleeding, but does not guarantee against it. Larger packs should be used in cases in which intraoperative blood loss was greater than normal. For patients with questionable hemostasis, the packing should remain for an additional one to two days beyond the standard 24 hours. At this period, the packing should be extracted partially to assess for bleeding around it before completely removing it. If slow oozing persists after pack removal, topical decongestants may be sprayed intranasally. Often, the vasoconstrictive effect will control such a problem. More severe bleeding may require replacing the packing material for another few days.

Rarely, bleeding continues beyond several days after surgery. In such cases, a careful intranasal examination with a rigid endoscope and suction may be required to identify the source of bleeding. Chemical cautery and repeat packing may address the problem. In some cases, an exam and electrocautery or suture control is required under anesthesia. In these cases, it may be an exposed vessel on the inferior turbinate or septum or granulation tissue around the septal splint which may be the source of the bleeding.

Postoperative infection is rare and is characterized by increased pain, swelling, and erythema. It must be determined if the patient has been compliant with the antibiotic regimen. If not, the appropriate antibiotics should be resumed. Nausea and dysphagia are two common reasons for failing to take oral medications. Antiemetics, liquid medicines, or i. v. administration of the antibiotics may therefore be needed. If infection has occurred despite taking antibiotics, a broader spectrum agent may be considered. If infection progresses despite these measures or if fluctuance develops, the intranasal incisions may need to be opened to allow drainage and irrigation beneath the SSTE. The presence of infection is compounded in the presence of multiple grafts or alloplastic materials.

Long-term complications related to collapse of nasal structures and contracture of the SSTE may manifest as lateral wall pinching, collapse of the middle vault, alar retraction, and tip ptosis. As stated previously, these complications are avoidable through stabilization of these structures and avoidance of overresection during primary surgery. These types of problems may not become apparent for several years after surgery. If severe, revision surgery to reconstruct the deficient areas may be required.

References

1. Toriumi DM. Structure approach in rhinoplasty. *Facial Plastic Clinics of North America*. 2000; 8:515–537.
2. Tardy ME. *Rhinoplasty: The art and science*. Philadelphia, W.B. Saunders: 1997.
3. Toriumi DM, Becker DG. *Rhinoplasty dissection manual*. Philadelphia: Lippincott: 1999.
4. Toriumi DM. Management of the middle nasal vault. *Op Tech Plast Reconst Surg* 1995; 2:16–30.
5. Orten SS, Hilger PA. Facial analysis of the rhinoplasty patient. In: Papel ID, ed. *Facial Plastic and Reconstructive Surgery*, 2nd ed. New York: Thieme Medical Publishers, Inc: 2002; 361–368.
6. Park SS. Treatment of the internal nasal valve. *Facial Plastic Clinics of North America*. 1999; 7:333–346.
7. Tardy ME, Walter MA, Patt BS. The overprojecting nose: anatomic component analysis and repair. *Facial Plastic Surgery*. 1993; 9:306–316.
8. Chand MS, Toriumi DM. Treatment of the external nasal valve. *Facial Plastic Clinics of North America*. 1999; 7:347–356.
9. Toriumi DM, Josen J, Weinberger M, Tardy ME. Use of alar batten grafts for correction of nasal valve collapse. *Arch Otolaryngol Head Neck Surg*. 1997; 123:802–8.
10. Toriumi DM, Hecht DA. Skeletal modifications in rhinoplasty. *Facial Plastic Clinics of North America*. 2000; 8:413–432.

Suggested Reading

- Tardy ME. *Rhinoplasty: The art and science*. Philadelphia: W.B. Saunders: 1997.
- Toriumi DM, Becker DG. *Rhinoplasty dissection manual*. Philadelphia: Lippincott: 1999.

